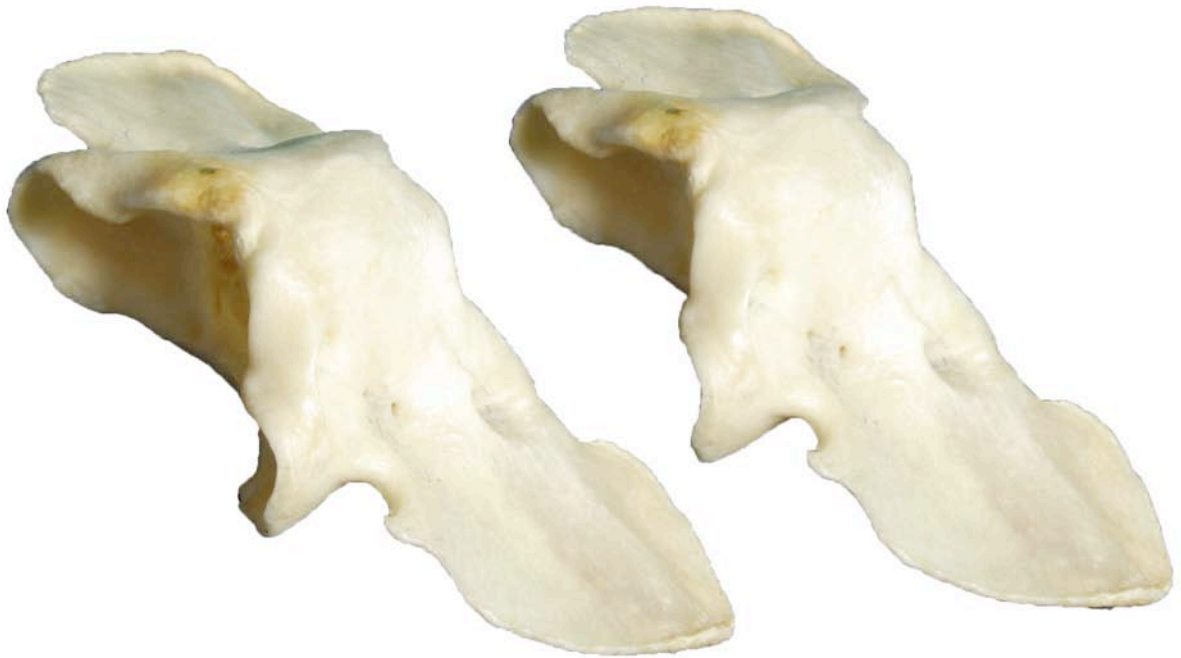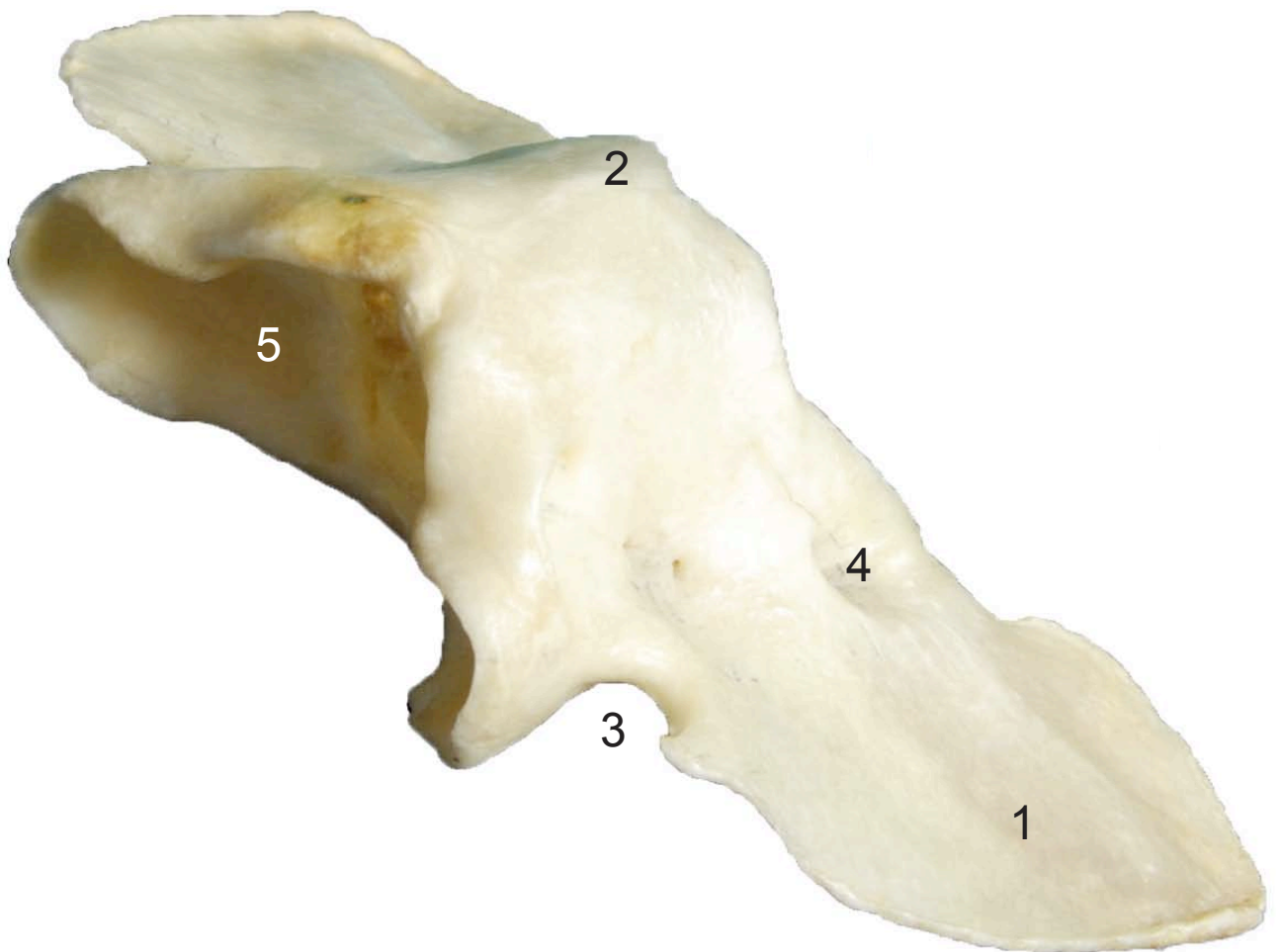

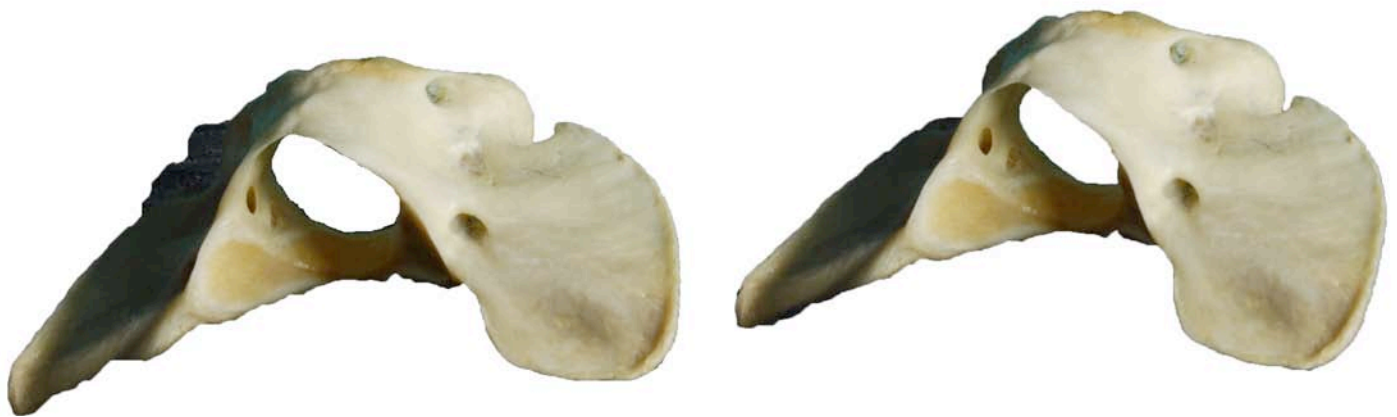
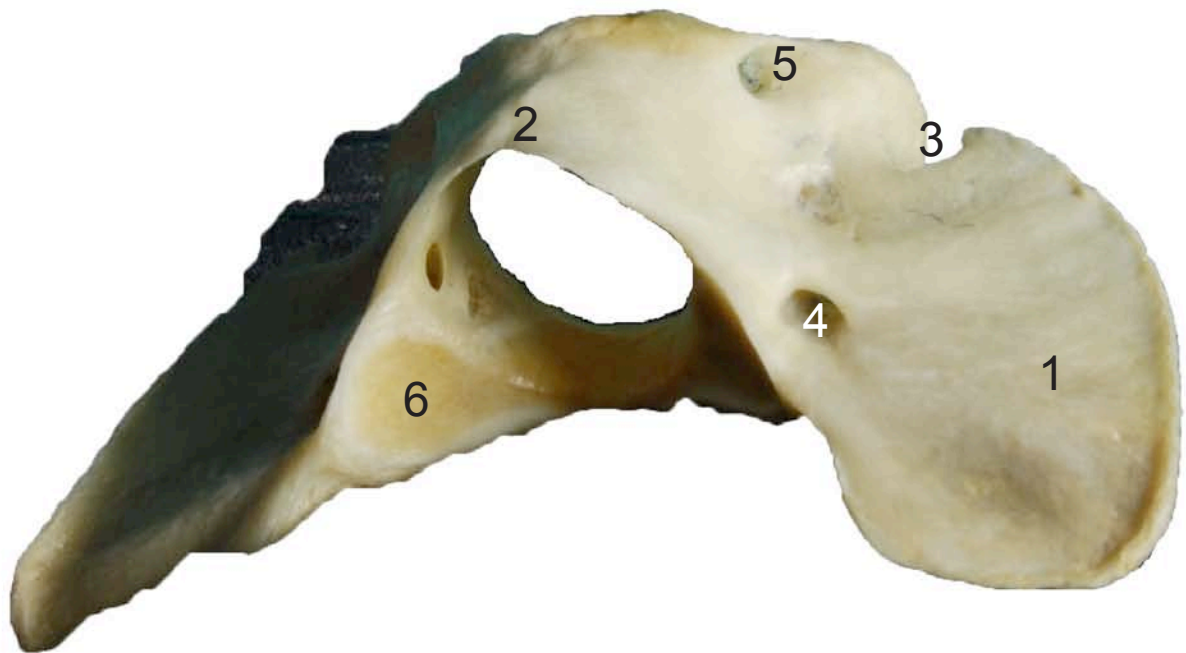


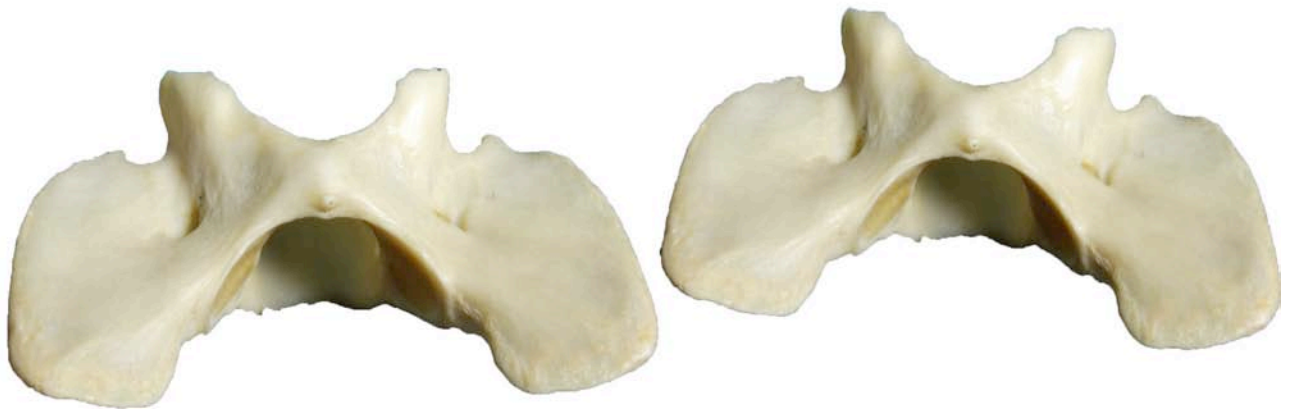- 1: Ala del atlas (Ala atlantis)
- 2: Tubérculo dorsal (Tuberculum dorsale)
- 3: Incisura alar (Incisura alaris)
- 4: Agujero trasverso (Foramen transversus)
- 5: Fosa articular craneal (Fovea articularis cranialis)



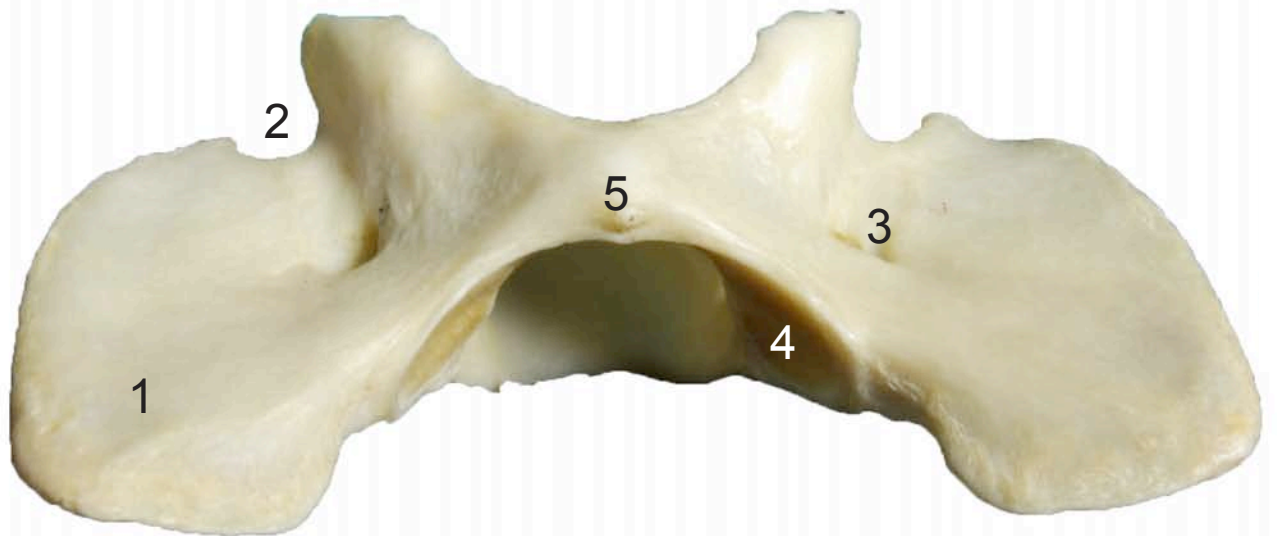


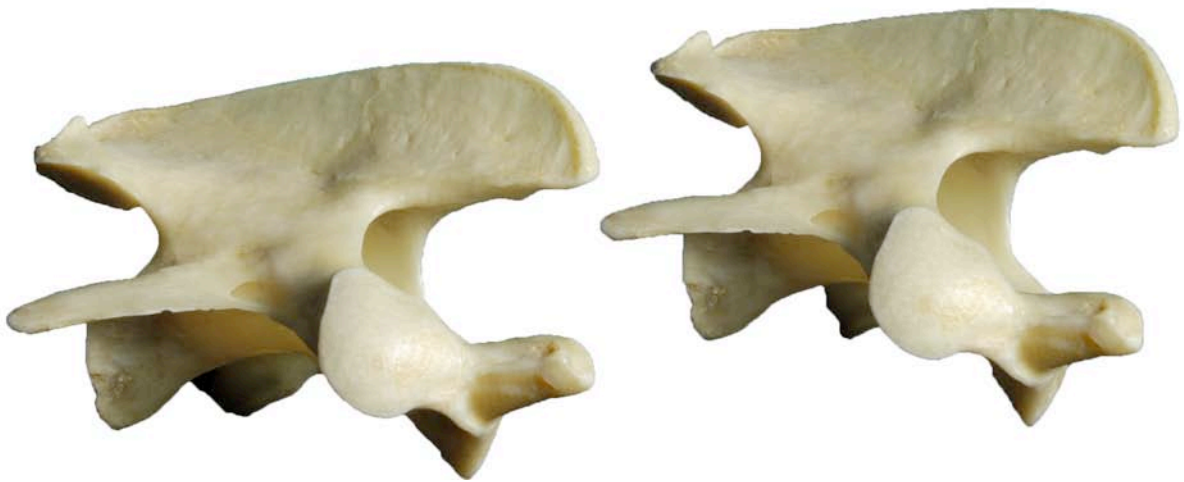- 1: Ala del atlas (Ala atlantis)
- 2: Tubérculo dorsal (Tuberculum dorsale)
- 3: Incisura alar (Incisura alaris)
- 4: Agujero trasverso (Foramen transversus)
- 5: Agujero vertebral lateral (Foramen vertebralis laterai)
- 6: Fosa articular craudal (Fovea articularis craudalis)





- 1: Ala del atlas (Ala atlantis)
- 2: Incisura alar (Incisura alaris)
- 3: Agujero trasverso (Foramen transversus)
- 4: Fosa articular caudal (Fovea articularis caudalis)
- 5: Tubérculo ventral (Tuberculum ventrale)

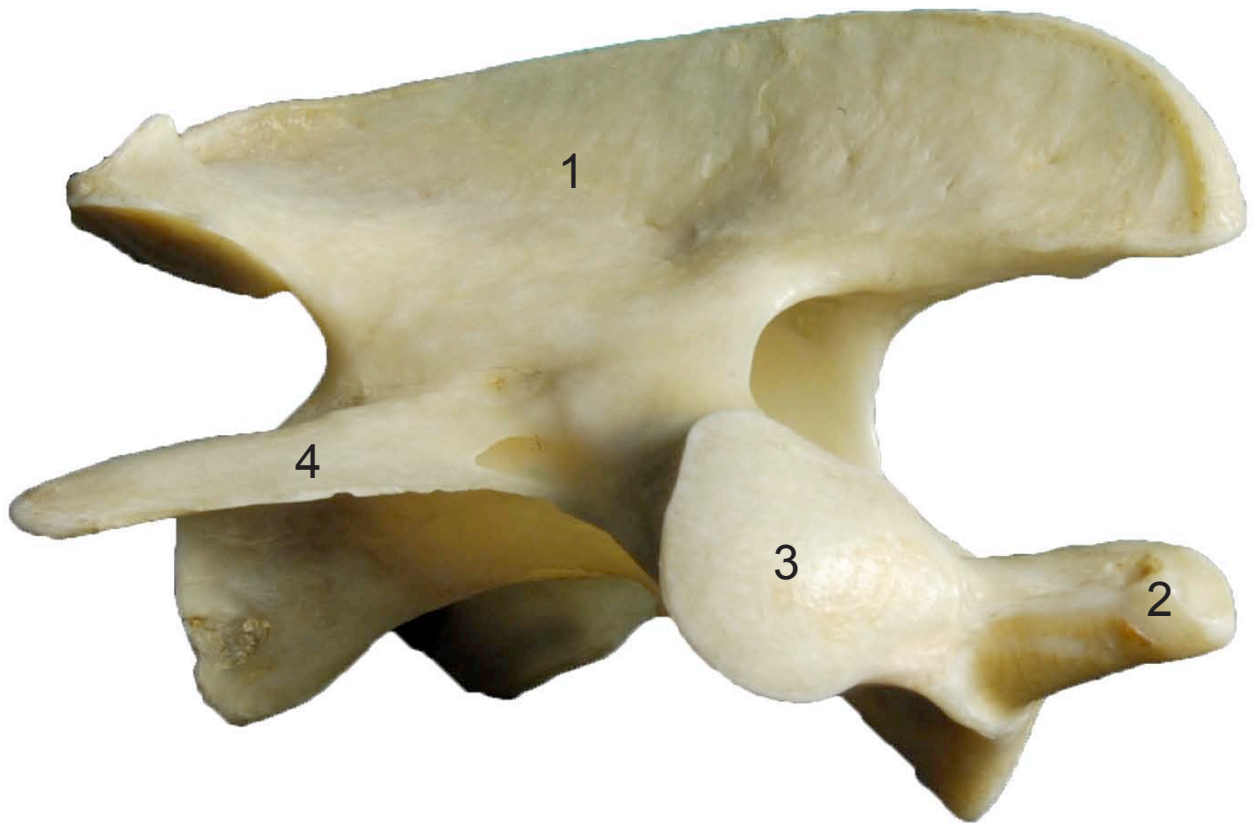




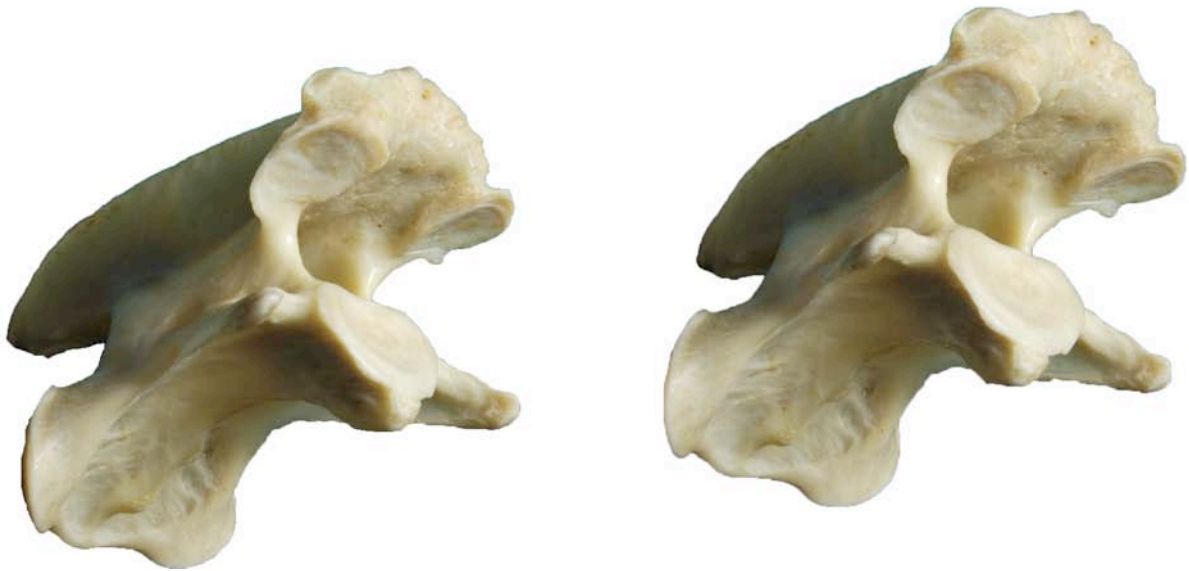- 1: Apófisis espinosa ( Processus spinosus)
- 2: Diente (Dens)
- 3: Cara articular craneal (Facies articularis cranialis)
- 4: Apófisis trasversa (Processus transversus)

AXIS  
AXIS

Craneo-lateral  
Cranialis-lateralis



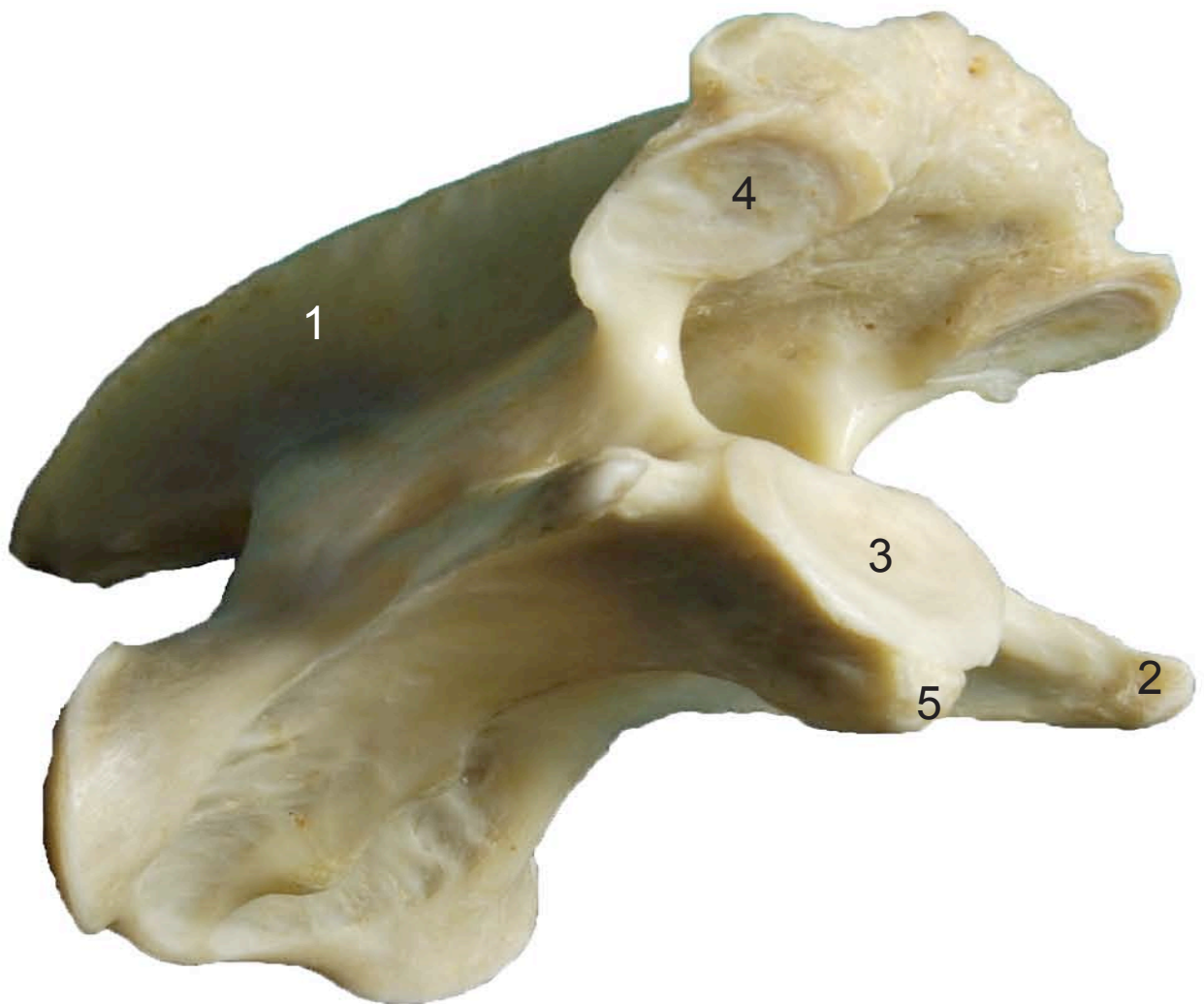


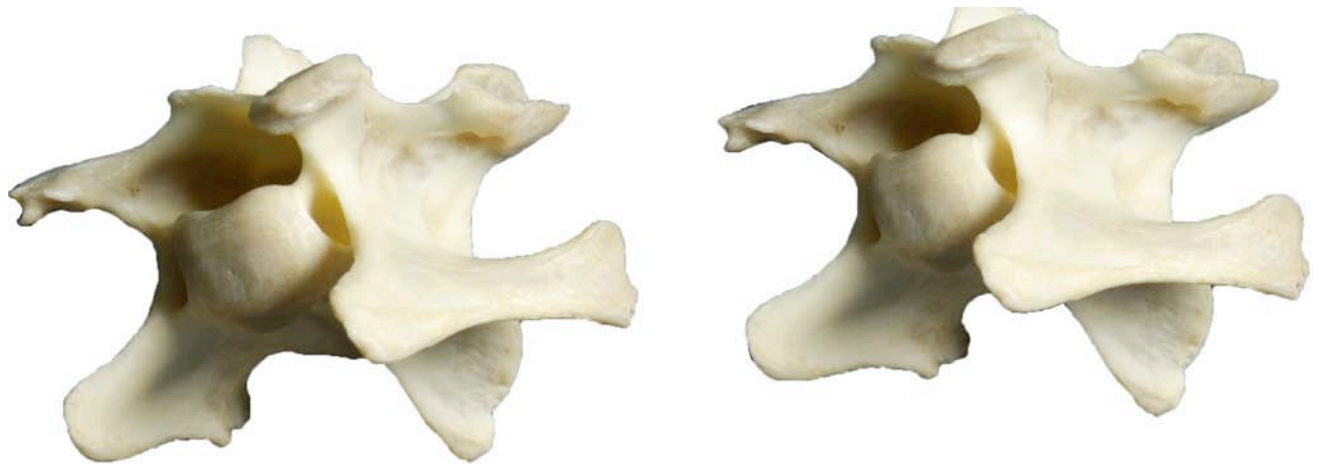

- 1: Apófisis espinosa ( Processus spinosus)
- 2: Apófisis trasversa (Processus transversus)
- 3: Fosa articular caudal (Fovea articularis caudalis)
- 4: Apófisis articular caudal (Processus articularis caudalis)
- 5: Tubérculo ventral (Tuberculum ventrale)

AXIS  
AXIS

Caudo-lateral  
Caudalis-lateralis

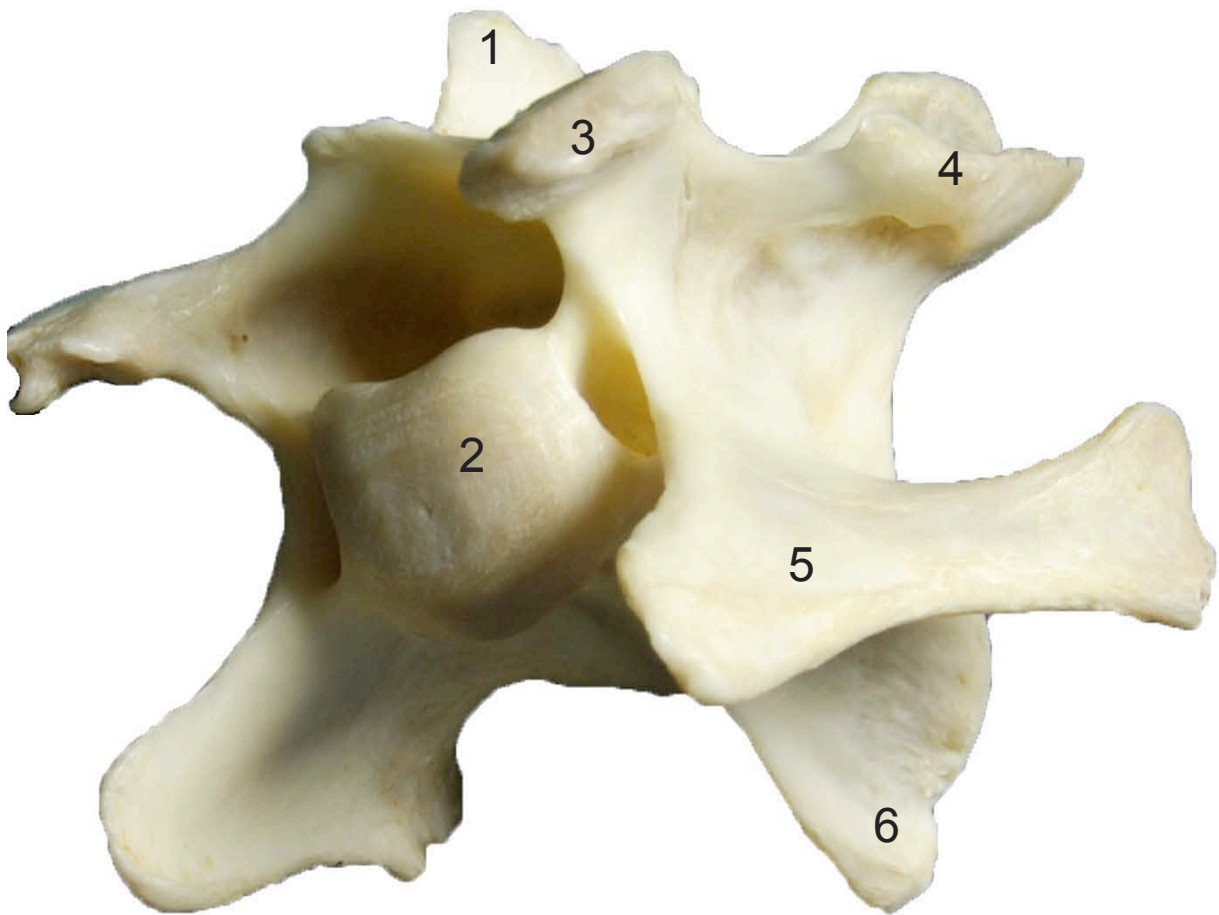


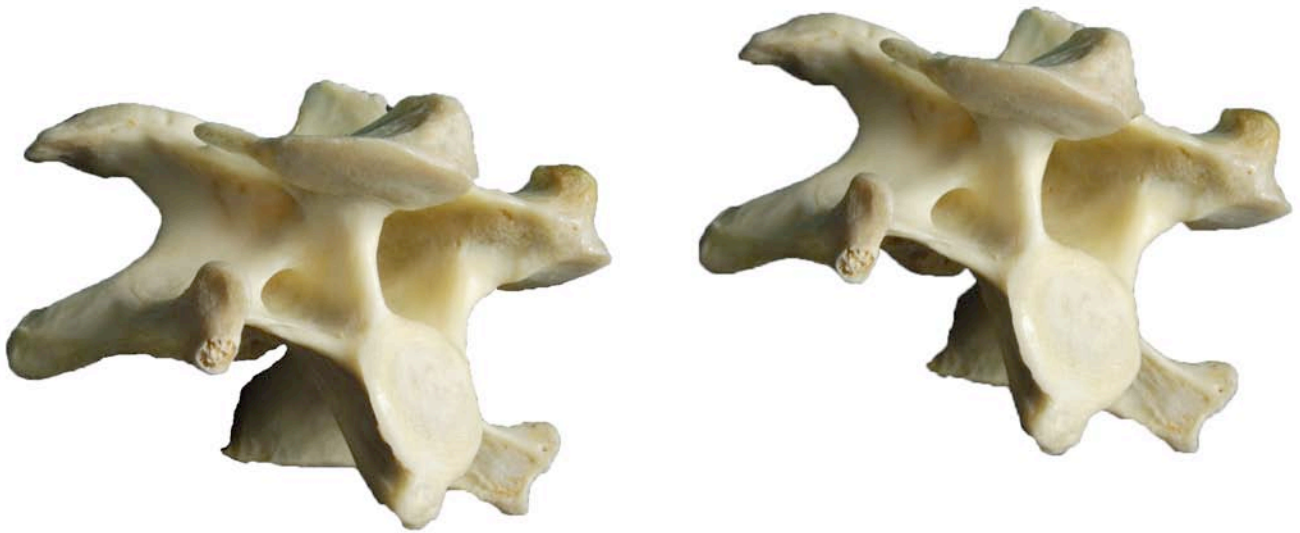

- 1: Apófisis espinosa ( Processus spinosus)
- 2: Cabeza de la vértebra (Caput vertebrae)
- 3: Apófisis articular craneall (Processus articularis craneals)
- 4: Apófisis articular caudal (Processus articularis caudalis)
- 5: Tubérculo dorsal (Tuberculum dorsale)
- 6: Tubérculo ventral (Tuberculum ventrale)

**CERVICAL (4)**  
**CERVICALIS (4)**

Craneo-lateral  
Cranialis-lateralis

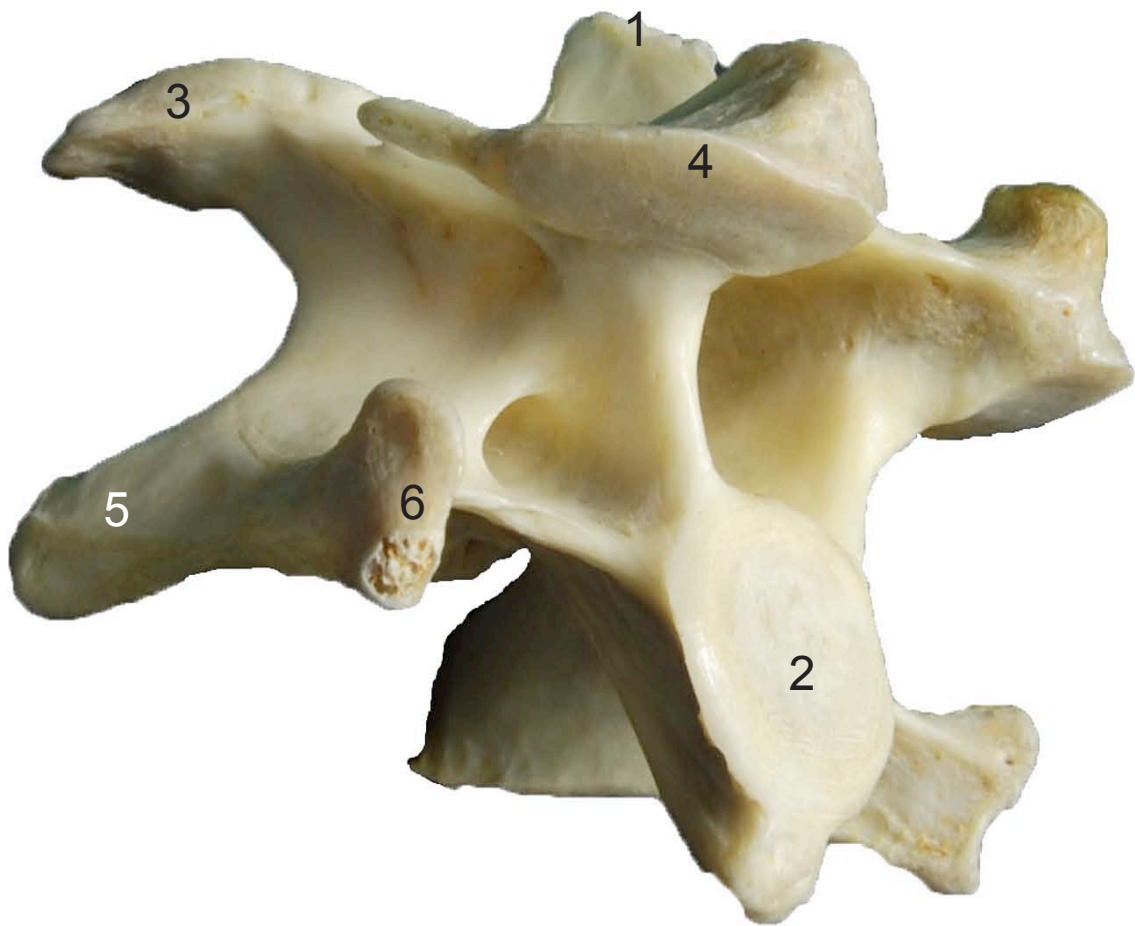


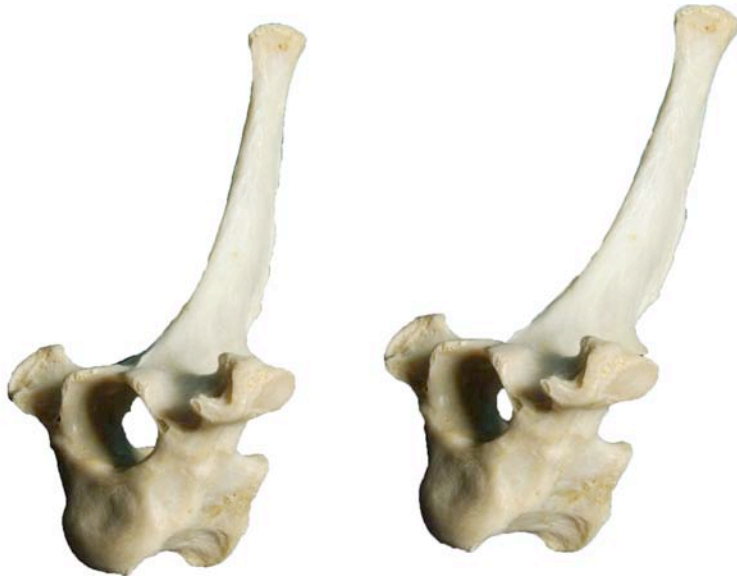

- 1: Apófisis espinosa ( Processus spinosus)
- 2: Fosa de la vértebra (Fossa vertebrae)
- 3: Apófisis articular craneall (Processus articularis craneals)
- 4: Apófisis articular caudal (Processus articularis caudalis)
- 5: Tubérculo dorsal (Tuberculum dorsale)
- 6: Tubérculo ventral (Tuberculum ventrale)

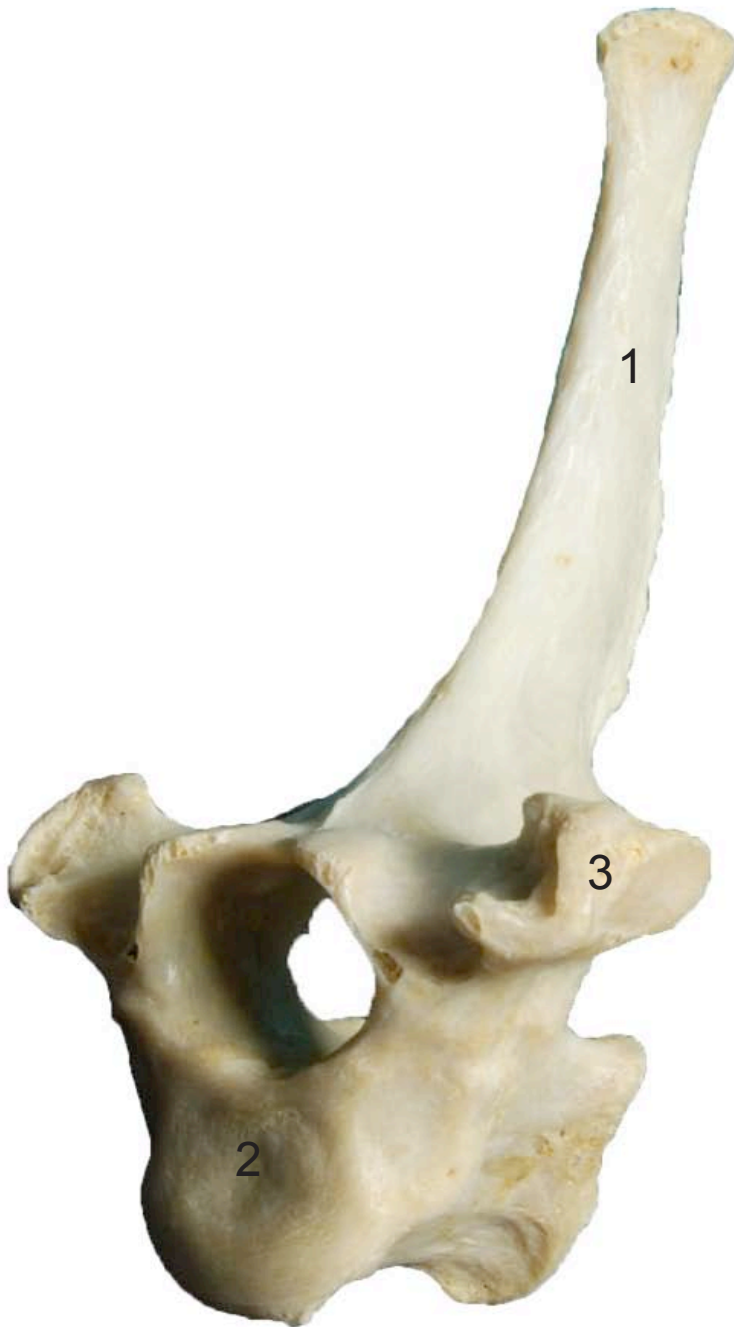**CERVICAL (4)**  
**CERVICALIS (4)**

Caudo-lateral  
Caudalis-lateralis

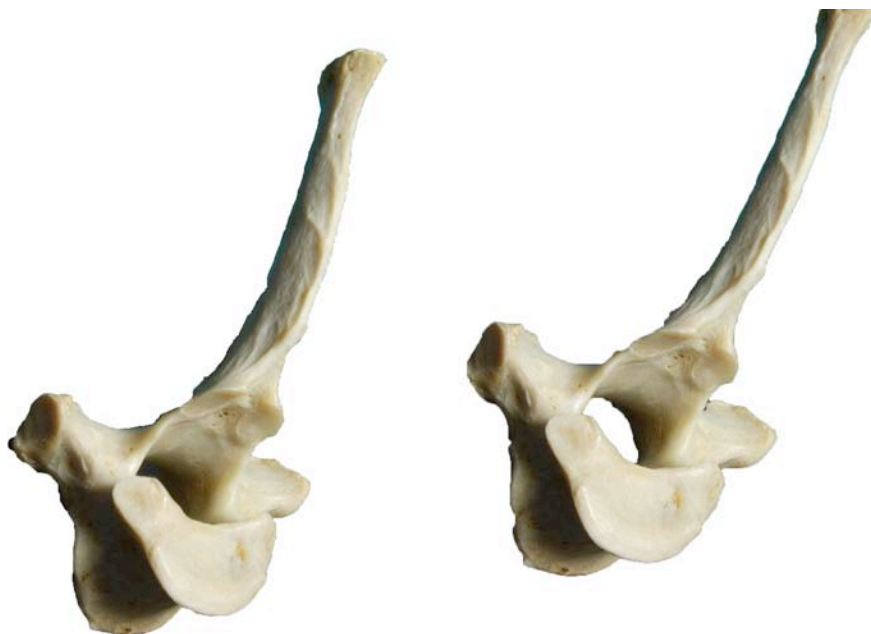



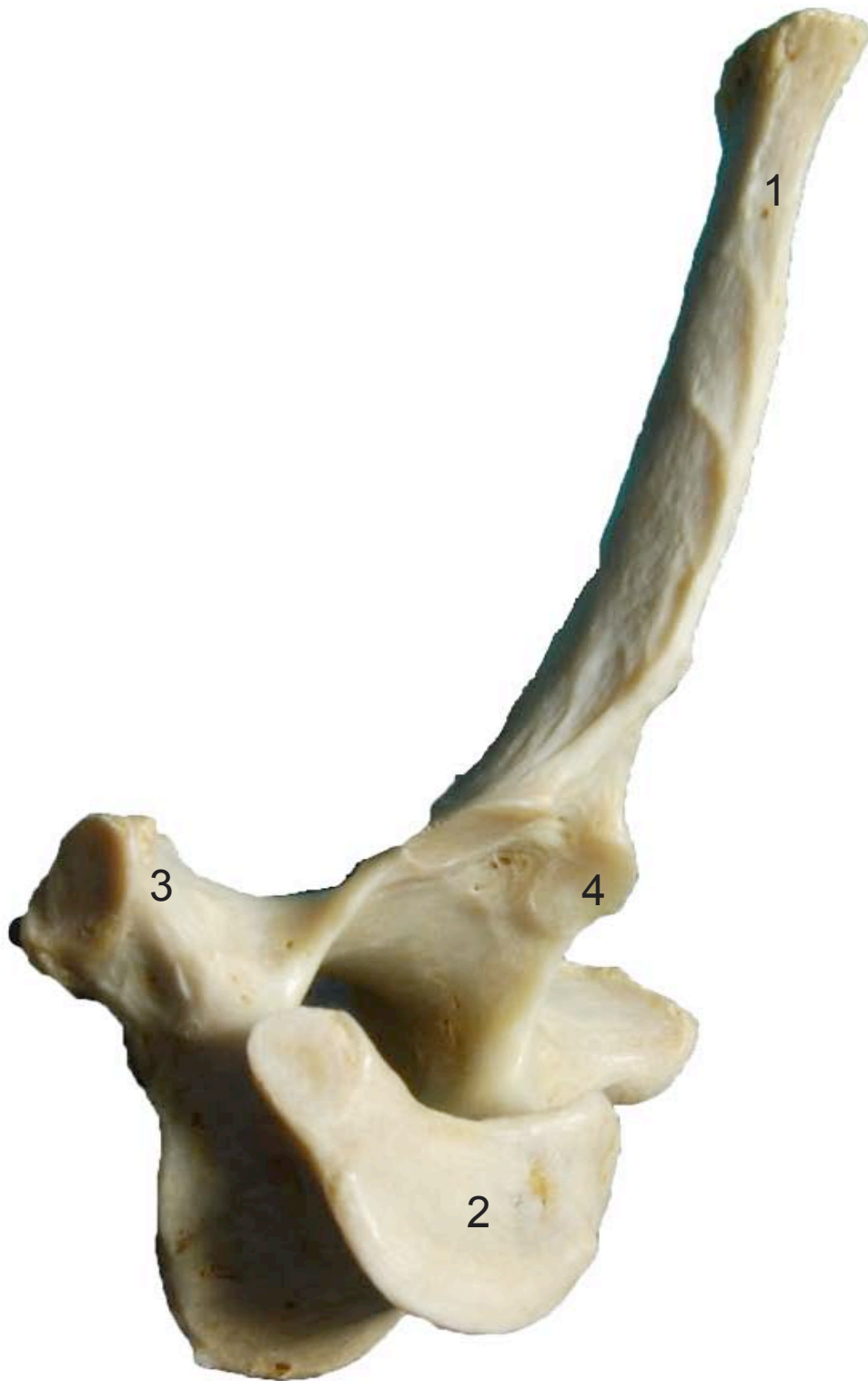- 1: Apófisis espinosa ( Processus spinosus)
- 2: Cabeza de la vértebra (Caput vertebrae)
- 3: Apófisis trasversa (Processus transversus)

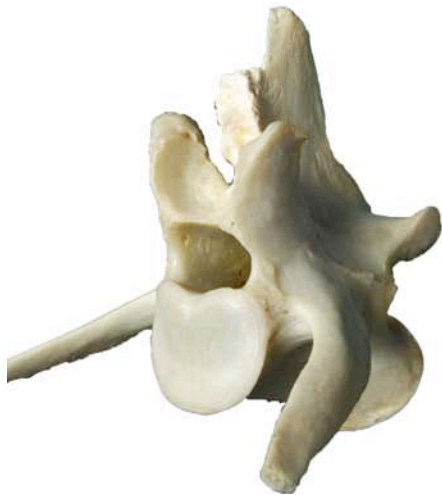



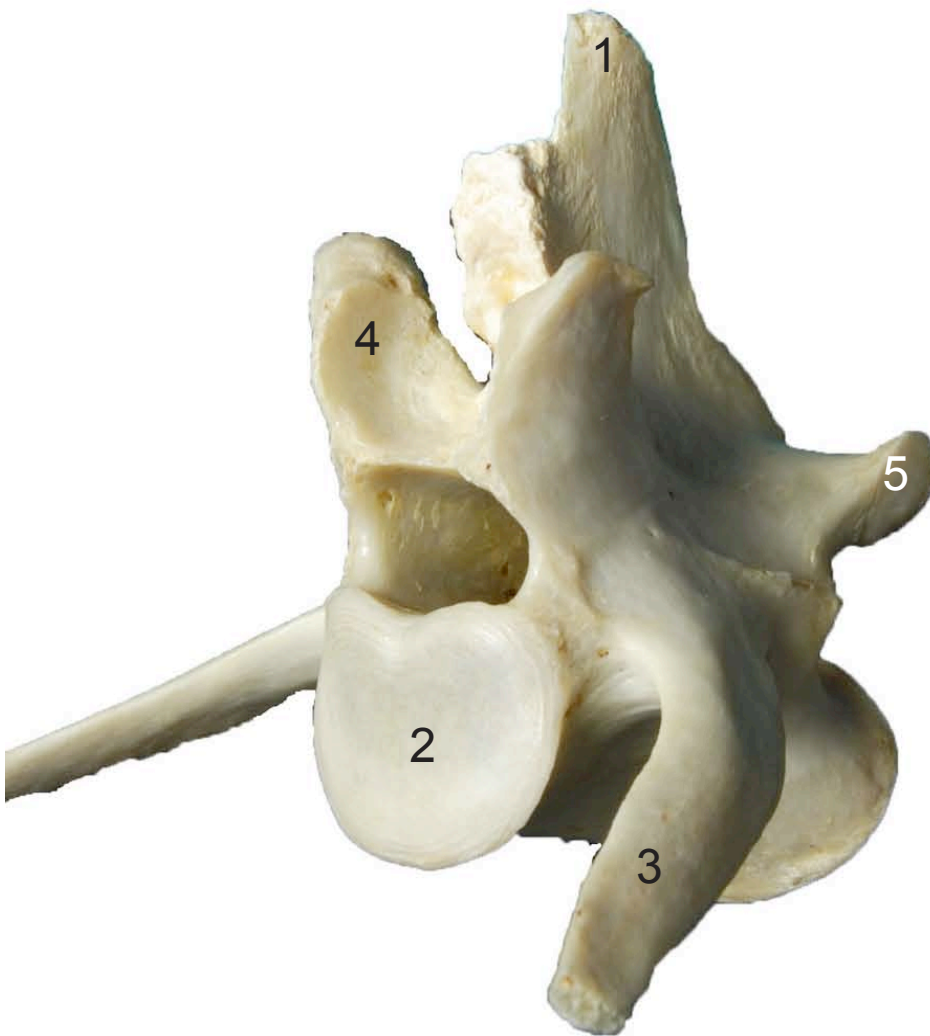


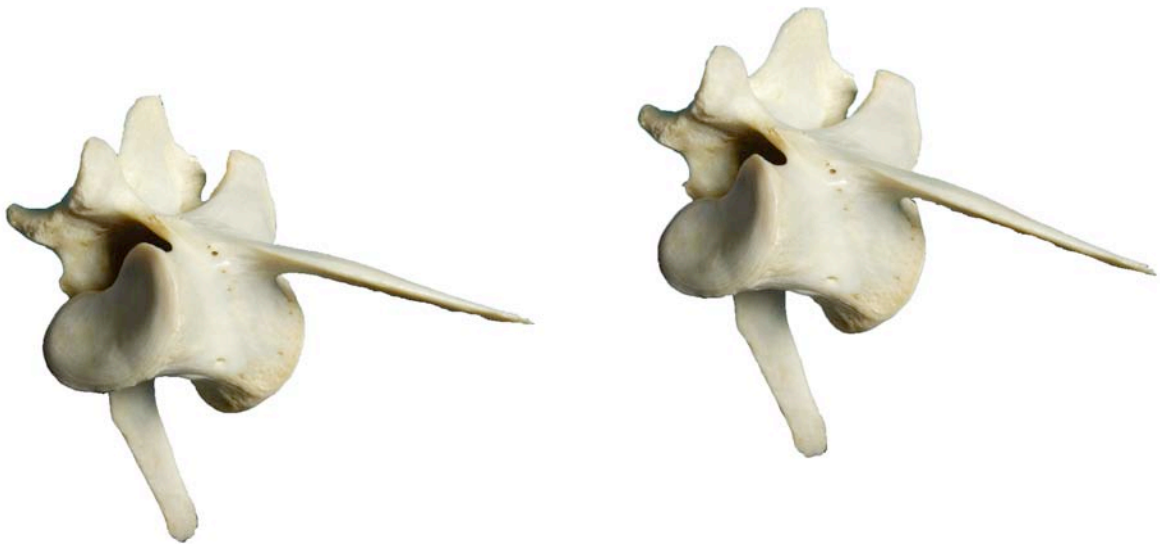
- 1: Apófisis espinosa ( Processus spinosus)
- 2: Fosa de la vértebra (Fossa vertebrae)
- 3: Apófisis trasversa (Processus transversus)
- 4: Carilla articular caudal (Facies articularis caudalis)





- 1: Apófisis espinosa ( Processus spinosus)
- 2: Cabeza de la vértebra (Caput vertebrae)
- 3: Apófisis trasversa (Processus transversus)
- 4: Apófisis articular craneall (Processus articularis craneals)
- 5: Apófisis articular caudal (Processus articularis caudalis)

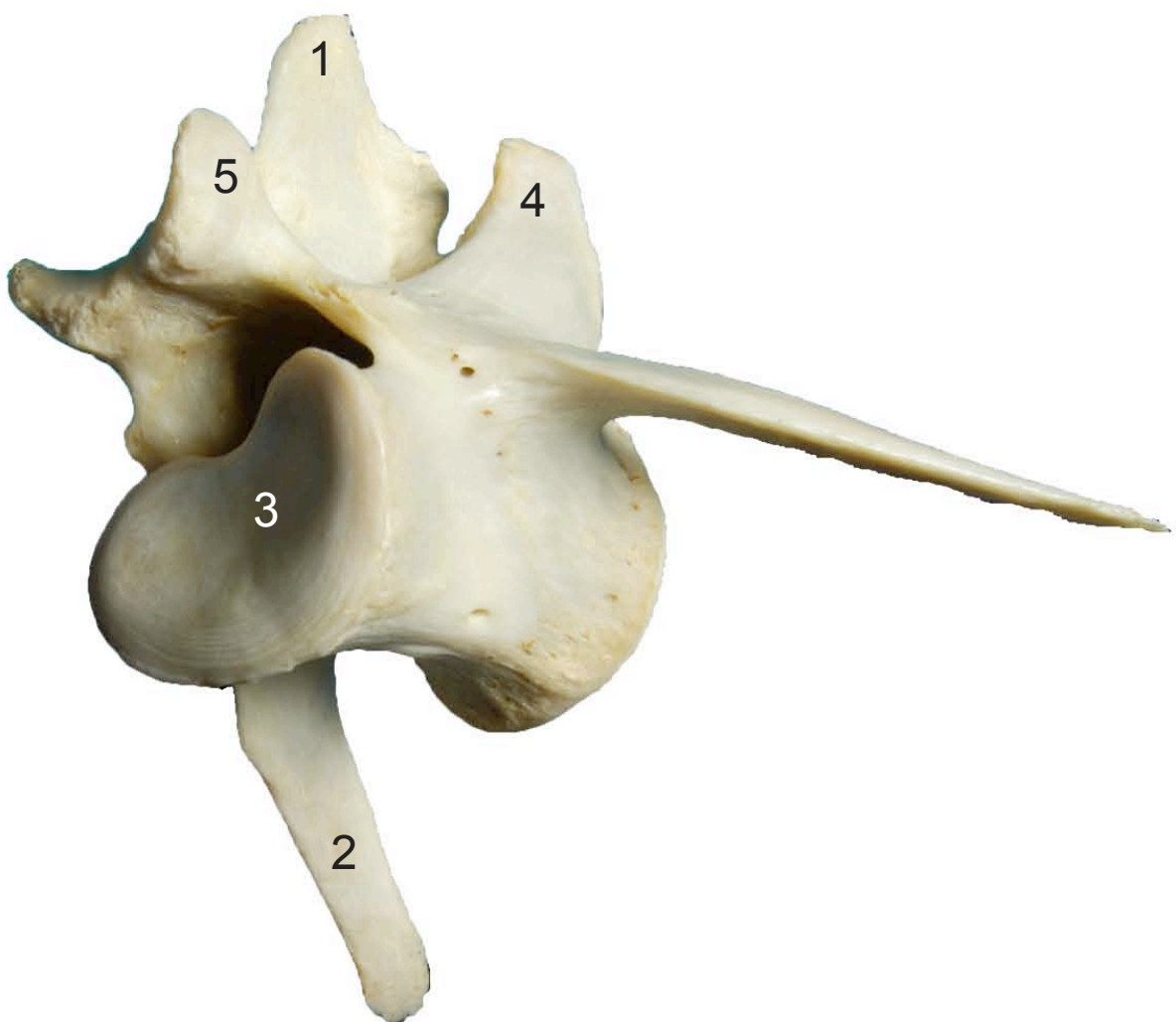




- 1: Apófisis espinosa ( Processus spinosus)
- 2: Fosa de la vértebra (Fossa vertebrae)
- 3: Apófisis trasversa (Processus transversus)
- 4: Apófisis articular craneall (Processus articularis craneals)
- 5: Apófisis articular caudal (Processus articularis caudalis)

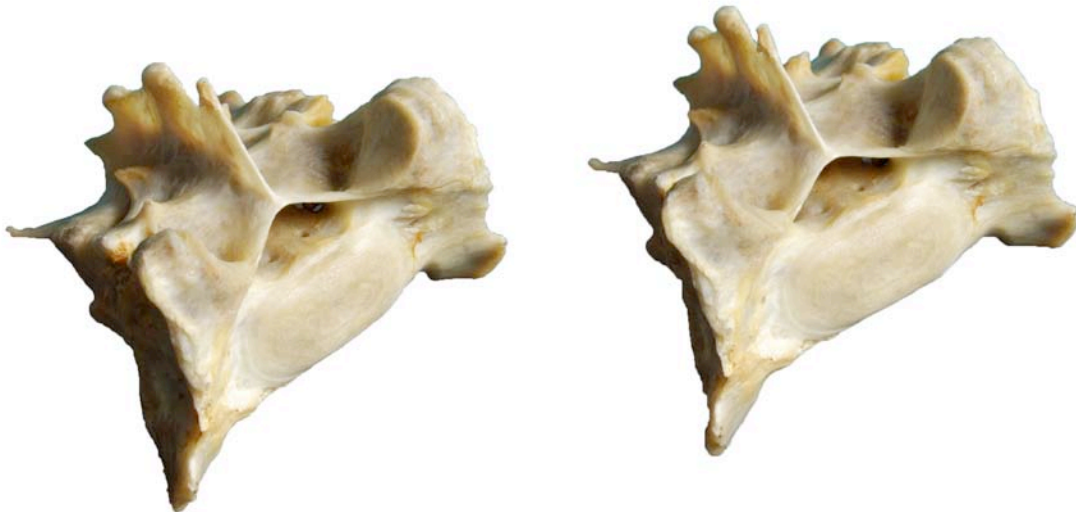**LUMBAR (5)**  
**LUMBARIS (5)**

Caudo-lateral  
Caudalis-lateralis



**SACRO  
OS SACRUM**

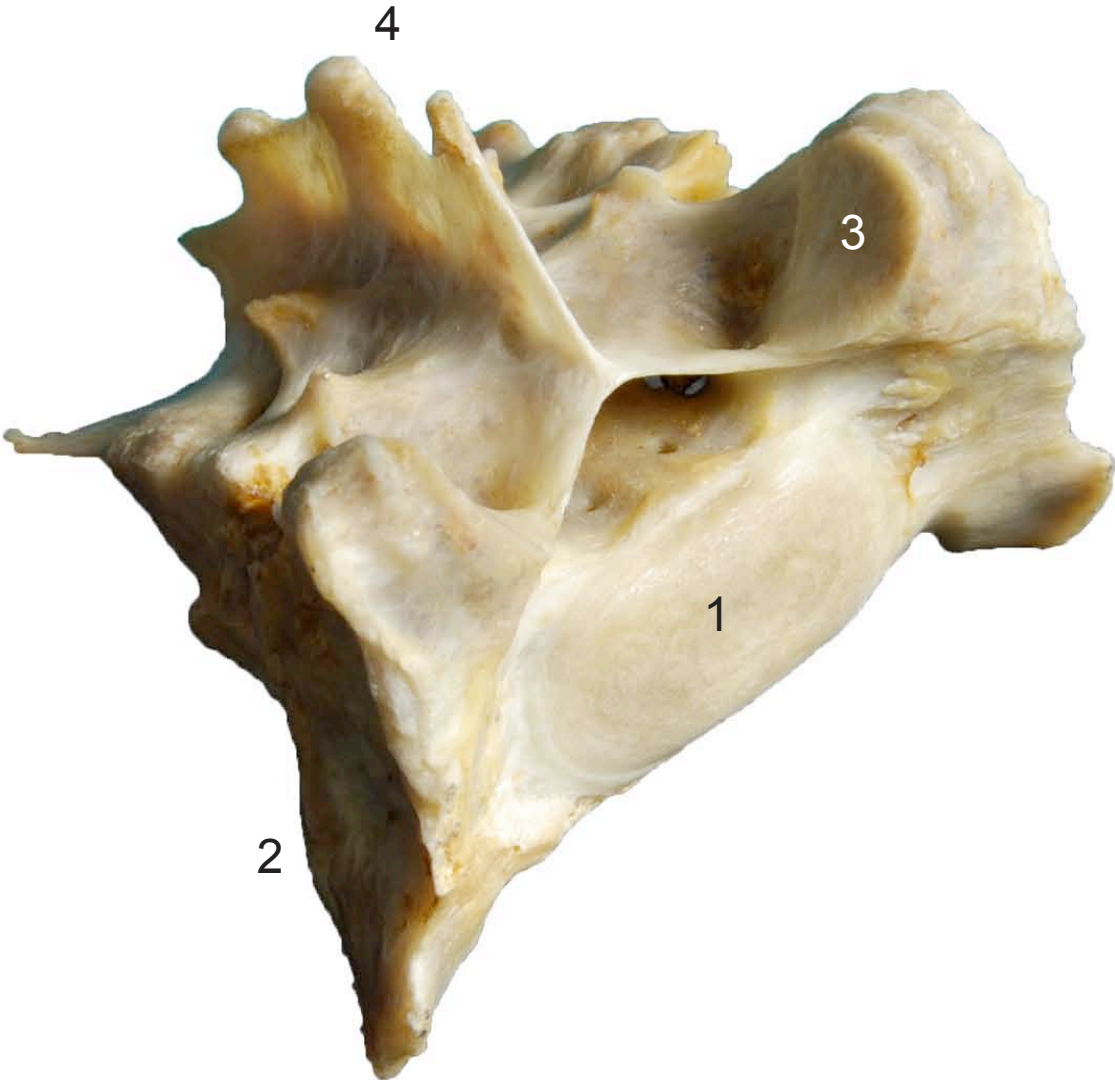
Craneo-lateral  
Cranialis-lateralis



- 1: Base del hueso sacro (Basis ossis sacri)
- 2: Ala del hueso sacro (Ala ossis sacri)
- 3: Apófisis articular craneal (Processus articularis cranialis)
- 4: Cresta sacra mediana (Crista sacralis intermedia)

**SACRO  
OS SACRUM**

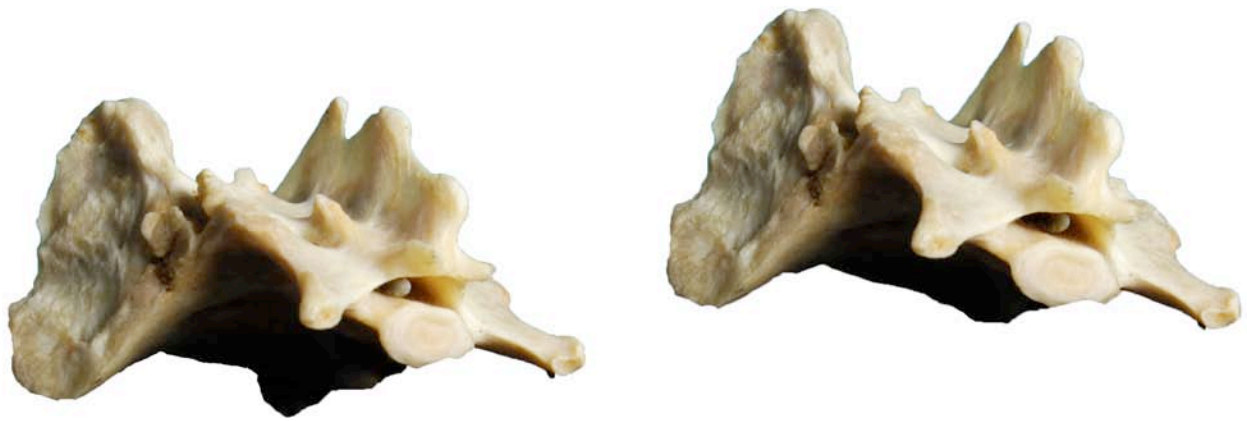Craneo-lateral  
Cranialis-lateraliss





**SACRO  
OS SACRUM**

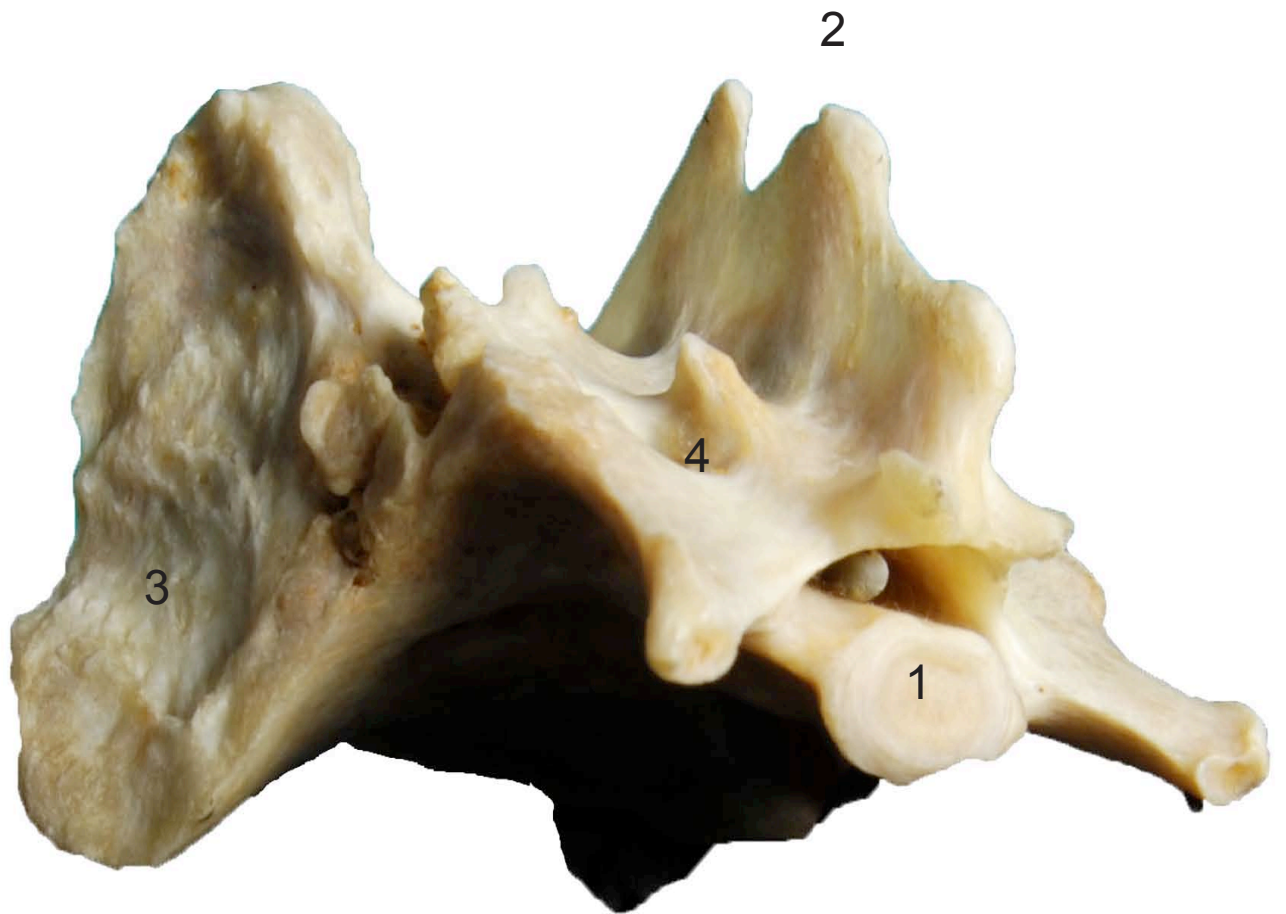
Caudo-lateral  
Caudalis-lateralis



- 1: Vértice del hueso sacro (Apex ossi sacri)
- 2: Cresta sacra mediana (Crista sacralis intermedia)
- 3: Cara auricular (Facies auricularis)
- 4: Agujero sacro dorsal (Foramen sacralia dorsalia)

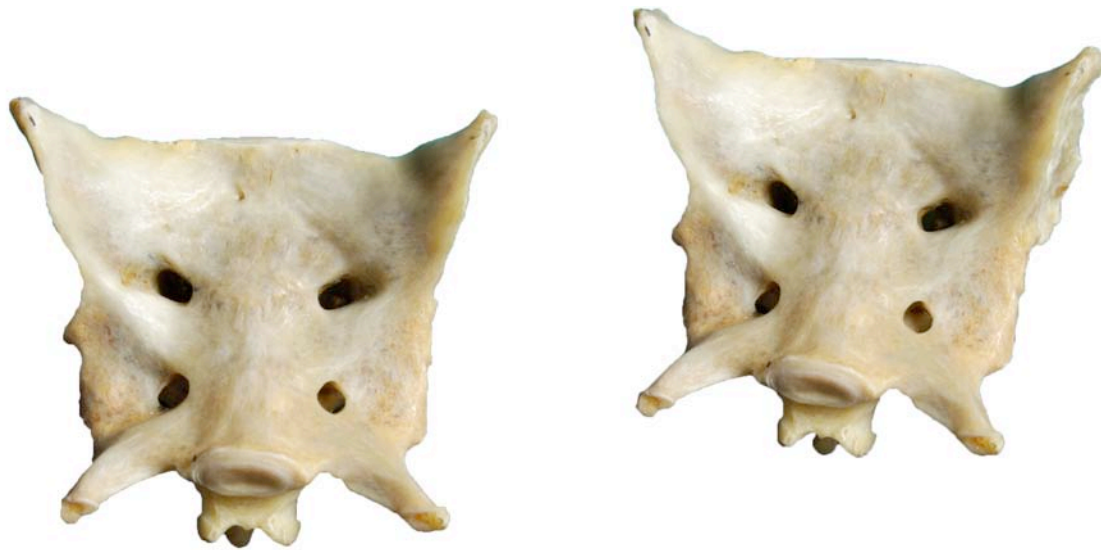**SACRO  
OS SACRUM**

Caudo-lateral  
Caudalis-lateralis



**SACRO  
OS SACRUM**

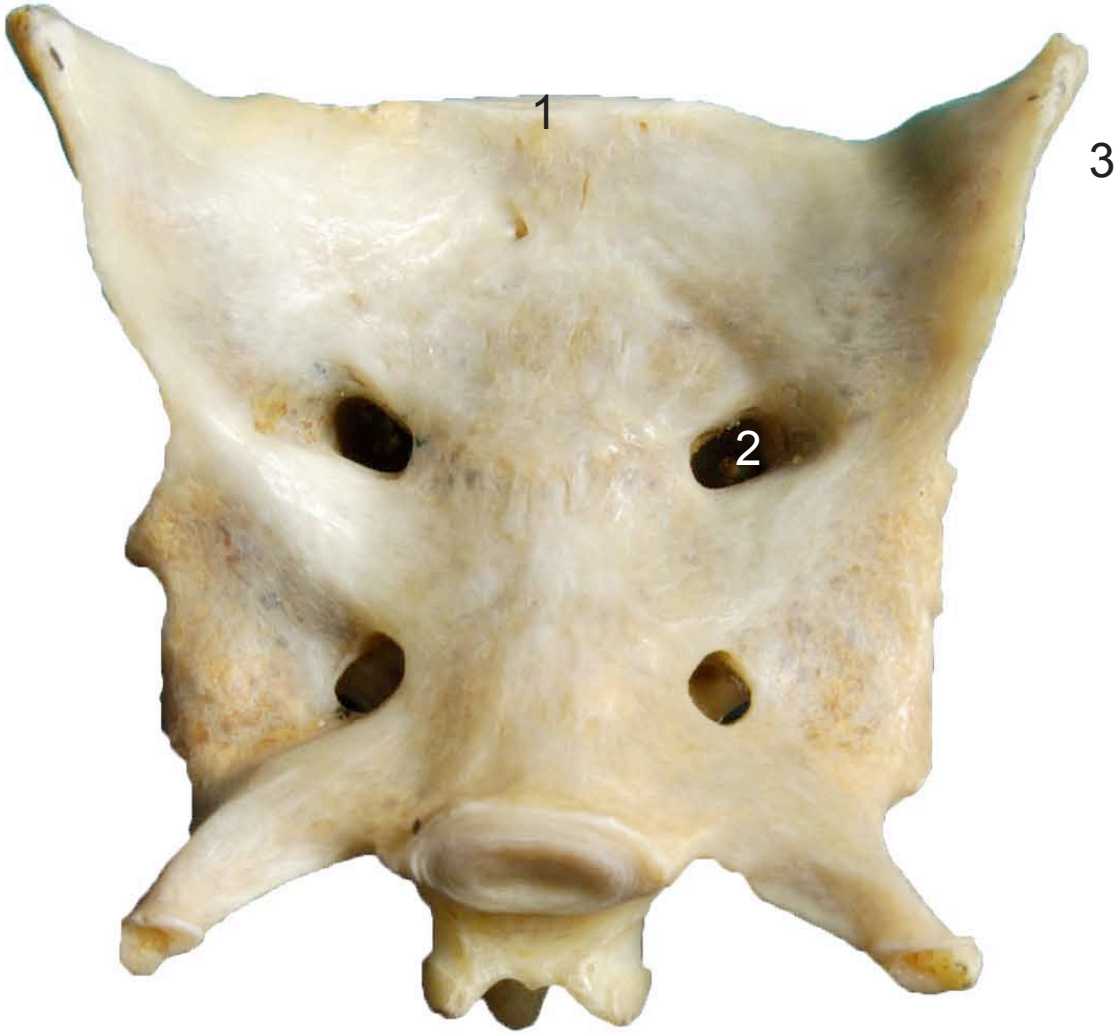Ventral  
Ventralis

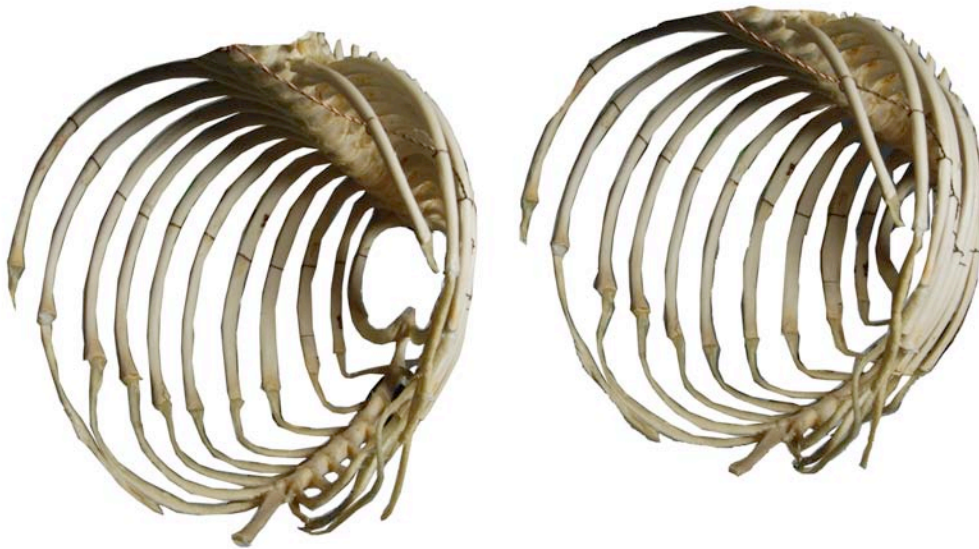

- 1: Promontorio (Promontorium)
- 2: Agujero sacro ventral (Foramen sacralia ventralia)
- 3: Ala del hueso sacro (Ala ossis sacri)

**SACRO  
OS SACRUM**

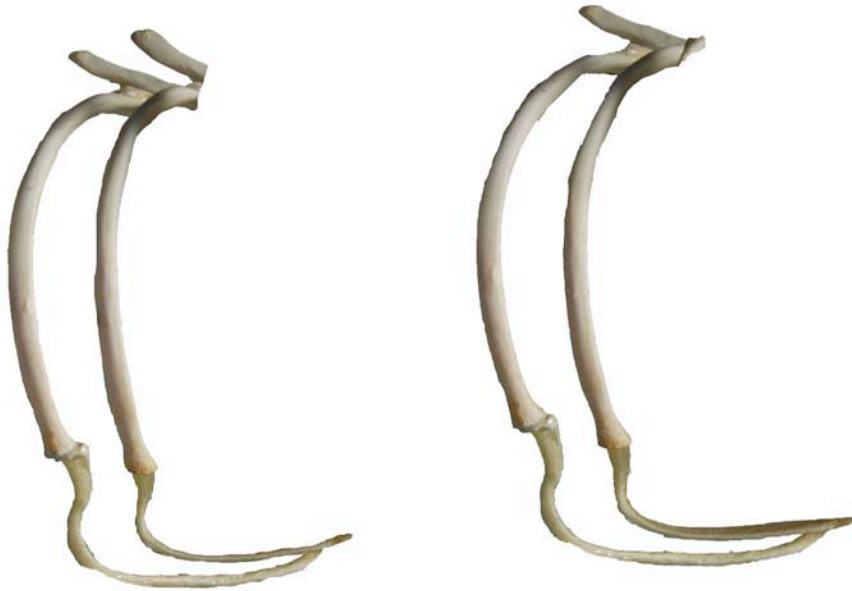Ventral  
Ventralis





- 1: Costillas asternales (*Costae spuriae*)
- 2: Costillas esternales (*Costae verae*)
- 3: Costilla flotante (*Costae fluctuantes*)
- 4: Rodilla costal (*Genu costae*)
- 5: Apófisis xifoides (*Procesus xiphoideus*)





- 1: Cabeza de la costilla (Caput costae)
- 2: Cuerpo de la costilla (Corpus costae)
- 3: Cartilago costal (Cartilago costalis)
- 4: Rodilla costal (Genu costae)
- 5: Cuello de la costilla (Collum costae)

**COSTILLAS  
COSTAE**

Lateral  
Lateralis







- 1: Manubrio (Manubrium sterni)
- 2: Apófisis xifoides (Procesus xiphoideus)
- 3: Esternebra (Sternebrae)
- 4: Sincondrosis interesternebral (Synchondrosis intersternebralis)

